CME CAST

EPISODE 3

Extraintestinal Manifestations in IBD — Screening, Referral Triggers, and Multidisciplinary Care Pathways

Supported by an independent educational grant from Merck & Co., Inc., Rahway, NJ, USA.

This activity may include discussions of products or devices that are not currently labeled for use by the U.S. Food and Drug Administration (FDA).

The faculty have been informed of their responsibility to disclose to the audience if they will be discussing off-label or investigational uses (any uses not approved by the FDA) of products or devices.



Amar Naik, MD

Director of Inflammatory Bowel Disease Program
Founding Partner
Midwest Digestive Health & Nutrition
Des Plaines, Illinois



Kimberly Orleck, PA-C

Physician Associate
Atlanta Gastroenterology Associates
Vice President of Advance Practice Providers
United Digestive
Atlanta, Georgia



Jason Schairer, MD

Co-Director
Henry Ford Inflammatory Bowel Disease Center
Detroit, Michigan

Learning Objectives

1. Identify common and high-impact EIMs associated with IBD
2. Integrate screening for EIMs using practical clinical workflows
3. Coordinate multidisciplinary management for patients with IBD with systemic involvement

EIM, extra-intestinal manifestations; IBD, Inflammatory bowel disease

Epidemiology of EIMs

Up to 50%

of people with IBD will develop at least one EIM at some point in their disease

~24-35%

have an active **musculoskeletal, dermatologic, or ocular** EIM at any given clinic visit

~26%

of EIMs appear before IBD is even diagnosed — not after

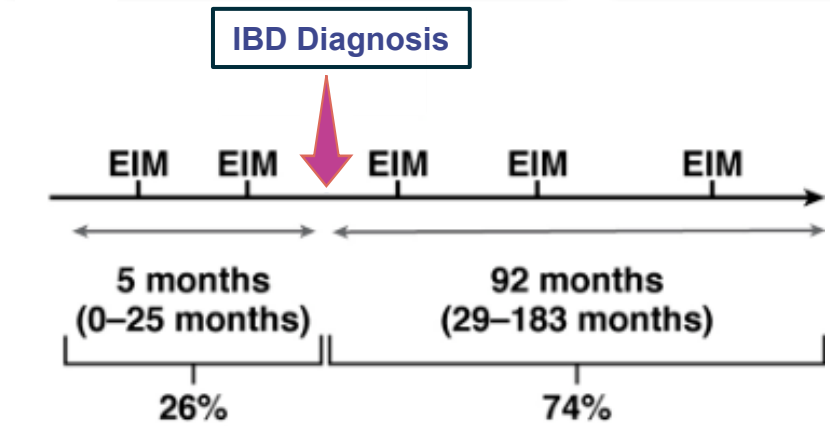

Many people w/IBD experience more than 1 EIM

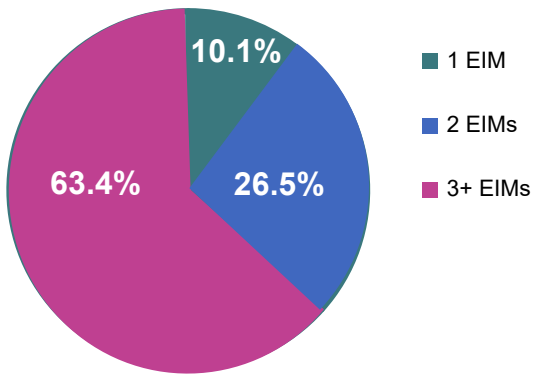

EIM(s) = extraintestinal manifestation(s); IBD = inflammatory bowel disease.

Gordon H, et al. *J Crohns Colitis.* 2024;18(1):1-37. Kilic Y, et al. *Inflamm Bowel Dis.* 2024;30(2):230-239. Nikiphorou E, et al. *Curr Rheumatol Rep.* 2020;22(9):55. Rogler G, et al. *Gastroenterology.* 2021;161(4):1118-1132. Youssef M, et al. *J Crohns Colitis.* 2024;18(9):1486-1504.

CME OUTFITTERS

Overall Burden of EIMs

Quality of Life & Long-Term Outcomes

QoL scores

- EIMs reduce disease-specific and health-related QoL independent of intestinal disease activity
- Joint pain, fatigue, and skin lesions rated among the most disabling aspects of IBD
- Patients often rate EIM impact above intestinal symptoms in daily life

Healthcare utilization

- Higher rates of hospitalization, IBD-related surgery, and treatment escalation vs. patients without EIMs
- EIMs contribute to total disease burden beyond intestinal symptoms

Work impairment

- Pooled overall work impairment 39.4%; presenteeism 35.9%; absenteeism 16.4%
- **One in three** IBD patients reported losing their job due to IBD

Diagnostic delay compounds burden

- Longer IBD diagnostic delay is associated with higher EIM burden and worse musculoskeletal outcomes
- Axial SpA: work disability affects up to 30% of AS patients
- **Early diagnosis and treatment improve work outcomes**

AS = ankylosing spondylitis; QoL = quality of life; SpA = spondyloarthritis.

Gordon H, et al. *J Crohns Colitis.* 2024;18(1):1-37. Kilic Y, et al. *Inflamm Bowel Dis*. 2024;30(2):230-239. Nikiphorou E, et al. *Curr Rheumatol Rep.* 2020;22(9):55. Rogler G, et al. *Gastroenterology*. 2021;161(4):1118-1132. Youssef M, et al. *J Crohns Colitis.* 2024;18(9):1486-1504.

CME OUTFITTERS

ECCO Guidance: Clinical Implications & Multidisciplinary Evaluation of EIMs

ECCO Guideline

Supports proactive multidisciplinary assessment of EIMs across joint, skin, eye, and hepatobiliary domains

Clinical Implications

Some EIMs parallel intestinal activity, but others may not; do not wait for a gut flare to evaluate possible organ-threatening

MDT Evaluation

Use symptom-triggered referral pathways to coordinate GI care with rheumatology, dermatology, ophthalmology, and hepatology

How This Changes Practice

Screen beyond the bowel

Ask routinely about joint pain or stiffness, skin lesions, red eye, photophobia, vision change, and cholestatic liver abnormalities because EIMs can precede or evolve outside bowel symptom patterns.

Refer urgently when vision is at risk

Suspected uveitis or scleritis requires prompt ophthalmology evaluation because delayed recognition can threaten vision and may not track intestinal activity

Differentiate parallel vs independent disease

Peripheral arthritis, episcleritis, and erythema nodosum often parallel intestinal inflammation, whereas axial disease, uveitis, and PSC may behave independently

Build a referral network

Coordinate GI care with rheumatology for axial or peripheral disease, dermatology for EN or PG, ophthalmology for ocular inflammation, and hepatology for PSC or AIH concerns.

AIH = autoimmune hepatitis; ECCO = European Crohn's and Colitis Organisation; EN = erythema nodosum; GI = gastrointestinal; MDT = multidisciplinary team. PG = pyoderma gangrenosum; PSC = primary sclerosing cholangitis.

Gordon H, et al. *J Crohns Colitis.* 2024;18(1):1-37. Kilic Y, et al. *Inflamm Bowel Dis.* 2024;30(2):230-239. Rogler G, et al. *Gastroenterology.* 2021;161(4):1118-1132.

CME OUTFITTERS

Evidence for Coordinated IMID Care in IBD

What does the evidence show when coordinated care models are *actually implemented*?

Referral Adherence & Disease Remission

586	102	$p<0.05$
IBD patients in cohort	dermatology & ophthalmology referrals	referral adherence → remission

- Adherence to dermatology and ophthalmology referrals was significantly associated with disease remission ($p<0.05$)
- Dermatology referrals were more preventive in nature; ophthalmology referrals more reactive — suggesting a prevention gap
- Proactive dermatologic surveillance may inform standardized referral frameworks across IBD-related specialties

IMID Clinic vs. Standard Referral

Comparative study: dedicated IMID multidisciplinary clinic (GI + derm + rheum) vs. conventional specialist referral

Significant reduction in EIM diagnostic delay and time to treatment in the IMID clinic vs. standard care **(log-rank $p<0.001$)**

- IMID clinic minimized care fragmentation and increased speed of treatment initiation vs. individual referral specialists
- IMID clinic group had higher rates of biologic optimization (switching/adding) vs. standard care ($p<0.05$)
- A dedicated multidisciplinary model can enhance EIM diagnosis and enable early intervention to prevent disease progression

IMID = immune-mediated inflammatory disease.

Bokaee SA, et al. *Cureus.* 2026;18(1):e102305. Gordon H, et al. *J Crohns Colitis.* 2024;18(1):1-37. Nardone OM, et al. *Therap Adv Gastroenterol.* 2025;18:17562848251323529.

CME OUTFITTERS

EIM Prevalence by Type: UC vs CD

A systematic review and meta-analysis

EIM Category	UC Prevalence	CD Prevalence
At Least 1 Joint, Ocular, or Skin EIM	27% (n=8,925)	35% (n=4,238)
Peripheral Joint	11% (n=67,286)	17% (n=40,786)
Axial Joint (SpA / Sacroiliitis)	4% (n=96,873)	5% (n=53,888)
EN	1% (n=112,389)	3% (n=59,801)
PG	1% (n=112,462)	1% (59,693)
Ocular Manifestations (Uveitis, Episcleritis, Scleritis)	2% (n=67,154)	3% (39,356)

Meta-analysis Overview

- 52 studies
- 352,454 patients

Key Takeaways

- EIMs are common in IBD
- Ocular, peripheral joint manifestations, and EN are more common in CD than UC
- Axial joint and PG are similar between UC and CD

Clinical Implication

- Early recognition and MDT management of EIMs can improve QoL

UC = ulcerative colitis; CD = Crohn's disease. Kilic Y, et al. *Inflamm Bowel Dis*. 2024;30(2):230-239.

CME OUTFITTERS

EIMs Extend Beyond Joint, Skin, and Eye Involvement

Key Point

EIMs are not limited to joint, skin, and eye manifestations

Broader organ-system awareness supports earlier recognition and multidisciplinary care

Additional organ systems that may be involved include:

Hepatobiliary
PSC
AIH

Pulmonary
Airway/interstitial involvement

Hematologic/ Vascular
Anemia, thrombosis

Cardiovascular
Systemic inflammatory burden

Neurologic
Neurologic complications

Renal/Metabolic
Nephrolithiasis, bone/metabolic effects

Oral/ENT
Aphthous and related manifestations

Psychological
Mood and psychosocial burden

ENT = ear, nose, throat/otolaryngology.
Harbord M, et al. *J Crohns Colitis*. 2016;10(3):239-254. Kilic Y, et al. *Inflamm Bowel Dis.* 2024;30(2):230-239.

CME OUTFITTERS

EIM Phenotypes — Two Clinical Frameworks

Framework 1 — Relationship to Gut Disease Activity

Some EIMs parallel intestinal activity, whereas others may follow a more independent course

Activity-Linked
parallels gut disease

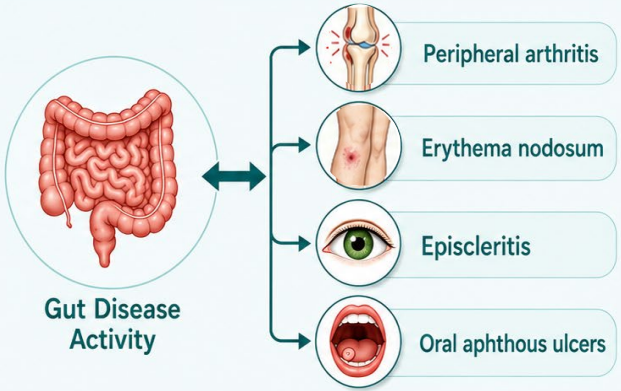

Implication: Controlling intestinal inflammation often improves the EIM — but local care may still be needed

Activity-Independent
follows own course

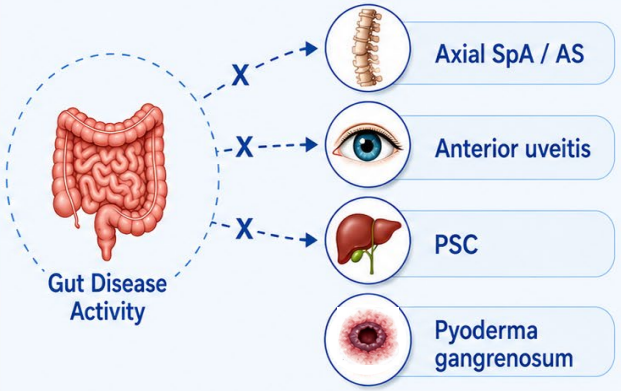

Implication: EIM flaring in gut remission ≠ treatment failure of IBD therapy — requires independent specialist-led management

AI-generated visual using ChatGPT version 5.5.

Gordon H, et al. *J Crohns Colitis.* 2024;18(1):1-37. Rogler G, et al. *Gastroenterology.* 2021;161(4):1118-1132.

CME OUTFITTERS

EIM Phenotypes — Two Clinical Frameworks (cont.)

Framework 2— Local Diagnosis/Treatment and Systemic Involvement

Some EIMs require local diagnosis and specialist treatment but also signal broader systemic inflammation

Example — Erythema nodosum

The skin nodule is a **LOCAL** lesion that may need local care (intralesional steroids, wound management).
At the same time, its presence signals **SYSTEMIC** inflammation — often active luminal disease,
sometimes co-occurring with other EIMs. Both dimensions need attention simultaneously.

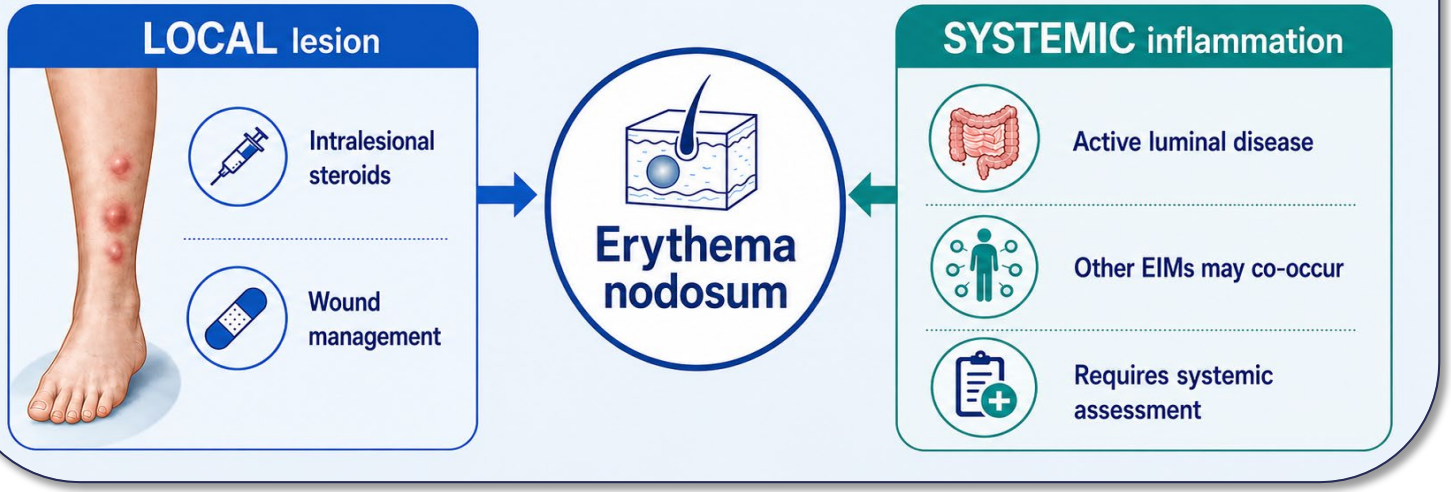

AI-generated visual using ChatGPT version 5.5.

Gordon H, et al. *J Crohns Colitis*. 2024;18(1):1-37. Rogler G, et al. *Gastroenterology*. 2021;161(4):1118-1132.

CME OUTFITTERS

Risk Factors for EIM Development



Genetic Predisposition
People with EIMs are more likely to have a family history

Smoking
Smoking appears to increase the risk of developing CD, affects disease course, and raises the risk of developing an EIM

Disease Duration
EIM risk appears to increase with longer IBD disease duration

IBD Disease Severity
More severe intestinal disease may be associated with greater EIM risk

Existing EIMs
Development of 1 EIM may increase the risk of developing another EIM in some people

Harbord M, et al. *J Crohns Colitis.* 2016;10(3):239-254. Hernández-Tejero M, et al. *Rev Esp Enferm Dig.* 2017;109(9):627-633.
Severs M, et al. *J Crohns Colitis.* 2016;10(4):455-461. Vavricka SR, et al. *Inflamm Bowel Dis.* 2015;21(8):1794-1800.

CME OUTFITTERS

Commonly Missed EIM Clues

1 Inflammatory back pain



Morning stiffness that improves w/movement may suggest axial involvement

2 Erythema nodosum



May parallel intestinal activity and should not be dismissed as a routine skin lesion

3 Fatigue + arthralgia



Consider both inflammatory and noninflammatory contributors when symptoms persist

4 Eye symptoms



Painful red eye, photophobia, or vision change requires urgent ophthalmologic assessment

5 Skin lesions

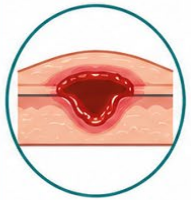

Consider EN or PG rather than routine wound disease

6 Therapy history



Prior and current therapy may influence symptom interpretation, including treatment-related complications



Clinical Pearl: Prevalence patterns can support recognition, but they should not be used alone to exclude an EIM.

AI-generated visual using ChatGPT version 5.5.

Gordon H, et al. *J Crohns Colitis.* 2024;18(1):1-37. Greuter T, et al. *Gut.* 2021;70(4):796-802. Faggiani I, et al. *Biomedicines.* 2024;12(8):1839.

CME OUTFITTERS

IBD-Associated Musculoskeletal Manifestations

Axial SpA / Ankylosing Spondylitis

- **Prevalence:** SpA occurs in up to 13% of patients with IBD; sacroiliitis ~10%, ankylosing spondylitis ~3%
- **IBD relationship:** Often activity-independent
- **Key symptom:** Inflammatory back pain: young onset, morning stiffness, improves with movement
- **Ask patients:** “Does your back pain get better as the day goes on or with movement?”
- **Referral:** Rheumatology referral is appropriate for an inflammatory pattern
- **Treatment note:** Monoclonal anti-TNF agents are generally preferred BUT avoid etanercept for IBD control

Peripheral Arthritis

Rheumatology now views this as a continuum rather than classic Type 1/Type 2; at referral centers the pattern is typically symmetric and persistent.

- **Prevalence:** Peripheral arthritis affects ~13% of people with IBD
- **Pauciarticular:** Few joints, often asymmetric, and may parallel gut activity
- **Polyarticular:** Multiple joints, often more persistent, and may behave independently of gut activity
- **Assessment:** Exclude septic arthritis and gout; assess joint count, symmetry, and relation to IBD activity
- **Note:** Treatment response varies; management should align with both musculoskeletal and intestinal disease goals

AI-generated visual using ChatGPT version 5.5.

TNF = tumor necrosis factor. Gordon H, et al. *J Crohns Colitis.* 2024;18(1):1-37. Karreman MC, et al. *J Crohns Colitis.* 2017;11(5):631-642. Nardone OM, et al. *Aliment Pharmacol Ther.* 2025;61(12):1854-1871.

CME OUTFITTERS

IBD-Associated Cutaneous Manifestations

ERYTHEMA NODOSUM (EN)

Prevalence: ~1-6% of IBD patients (UC: 1-3% | CD: 3-6%)



CLINICAL PATTERN

- Tender, erythematous nodules, typically on the anterior shins; associated with active IBD.

LOCAL CARE

- Rest, leg elevation, compression
- NSAIDs with caution in IBD
- Topical or intralesional steroids if needed

SYSTEMIC MEANING

- Treat underlying IBD flare
- EN usually resolves with control of bowel inflammation
- May coexist with other EIMs

PYODERMA GANGRENOSUM (PG)

Prevalence: ~1% of IBD patients (UC: 1% | CD: 1%)

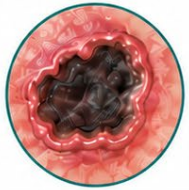

CLINICAL PATTERN

- Painful, rapidly enlarging necrotic ulcer; often at trauma or surgical sites due to pathergy.

LOCAL CARE

- Wound care only

DEBRIDEMENT CONTRAINDICATED (risk of pathergy)

SYSTEMIC TREATMENT*

- Corticosteroids (first-line)
- Biologics (e.g., infliximab, adalimumab)
- Other immunosuppressants if needed
- Multidisciplinary management

PSORIASIFORM / PARADOXICAL LESIONS

Paradoxical reaction reported in anti-TNF-treated patients (frequency varies across studies)



CLINICAL PATTERN

- Psoriasiform lesions developing after initiation of anti–TNF therapy; a paradoxical cutaneous side effect.

MANAGEMENT: STEPWISE*

1. Topical treatment with steroids / coal tar
2. Dermatology co-management
3. Consider biologic switch only if topical treatment fails and IBD control is adequate

KEY PRINCIPLE

- Avoid early switching of effective IBD therapy; most cases can be managed medically.

*Corticosteroids, infliximab, adalimumab, and other immunosuppressants for pyoderma gangrenosum, and topical steroids, coal tar represent off-label use.

AI-generated visual using ChatGPT version 5.5.

NSAIDs = non-steroidal anti-inflammatory.

Antonelli E, et al. *J Clin Med.* 2021;10(2):364. Faggiani I, et al. *Biomedicines*. 2024;12(8):1839. Greuter T, et al. *Clin Rev Allergy Immunol.* 2017;53(3):413-427. Kilic Y, et al. *Inflamm Bowel Dis*. 2024;30(2):230-239.

CME OUTFITTERS

IBD-Associated Ocular Manifestations

Episcleritis

Activity-LINKED | Routine referral

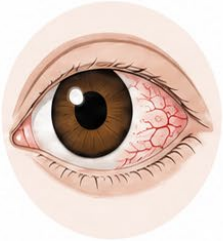

Superficial episcleral inflammation. Redness, mild discomfort, no vision change. Self-limiting; parallels IBD activity. May resemble conjunctivitis — confirm with slit-lamp.

Management:* Topical NSAIDs or steroids; treat IBD activity

Scleritis

Activity-INDEPENDENT | Urgent – within 1 week

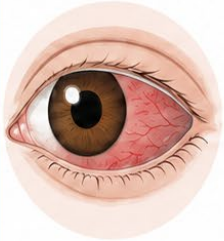

Deep scleral inflammation. Severe boring eye pain, photophobia, tenderness to palpation. Risk of scleral thinning and perforation. Requires systemic therapy.

Management:* Ophthalmology-led. Systemic NSAIDs or corticosteroids first-line; immunosuppressants or anti-TNF if refractory

Anterior Uveitis

⚠ Activity-INDEPENDENT | Same-day / 24–48h



Uveal tract inflammation. Eye pain, photophobia, blurred vision, circumlimbal redness. Most common serious ocular EIM. Irreversible vision loss if untreated. IBD therapy alone is often insufficient — uveitis follows its own course.

Management:* Ophthalmology mandatory; topical/systemic corticosteroids for acute onset; methotrexate or azathioprine for recurrent/chronic symptoms; anti-TNF (infliximab preferred) for refractory conditions

Red flag: Eye pain + photophobia + vision change in any IBD patient = same-day ophthalmology.
Uveitis can cause irreversible vision loss within hours to days if untreated.

*Topical NSAIDs and steroids for episcleritis; systemic NSAIDs, corticosteroids, immunosuppressants, and anti-TNF agents for scleritis; and corticosteroids, methotrexate, azathioprine, and infliximab for anterior uveitis represent off-label use.

AI generated visual using ChatGPT version 5.5

CME OUTFITTERS

Possible Anti-TNF Suppression/Unmasking Effect

Anti-TNF agents have broad anti-inflammatory activity-suppressing multiple immune pathways, including those that drive EIMs. When the anti-TNF is switched to a non-TNF biologic, a **previously suppressed EIM may become clinically apparent**.

1 — Anti-TNF Therapy Active

→ Individual on infliximab, adalimumab, or golimumab
→ IBD controlled
→ EIMs suppressed

2 — Switch to Non-TNF Biologic

→ Vedolizumab, ustekinumab, or risankizumab initiated — due to non-response, secondary failure, or safety

3 — New EIM Appears

→ Joint pain, skin lesion (EN, PG), or eye inflammation develops within weeks to months of the switch

✗ WRONG ASSUMPTION

Clinician & patient attribute the new EIM to the new biologic

→ Drug is switched again
→ Underlying EIM goes untreated
→ Specialist never consulted

✓ CORRECT APPROACH

Recognize unmasking — not drug toxicity

→ Incorporate a specialist (rheum/derm/ophtho)
→ Treat the EIM directly
→ Reassess biologic need separately

Clinical Pearl: Before attributing a new EIM to a non-TNF biologic, ask*: was prior anti-TNF therapy suppressing this EIM?*
The new drug's mechanism doesn't target the same pathway — unmasking is the more likely explanation.
Referring to a specialist, not a biologic switch, is the preferred next step.

Faggiani I, et al. *Biomedicines.* 2024;12(8):1839. Gordon H, et al. *J Crohns Colitis.* 2024;18(1):1-37. Nardone OM, et al. *Aliment Pharmacol Ther.* 2025;61(12):1854-1871.

CME OUTFITTERS

Case Vignette 1 — Gut Remission, Systemic Flare

Patient Presentation

Age / IBD:	44-year-old man; CD (ileocolonic) — recently achieved endoscopic remission on vedolizumab
Gut status:	CRP normal, fecal calprotectin 80 — no active luminal disease
Chief complaint:	Worsening low back pain × 3 months; morning stiffness lasting ~1 hour, improves with activity
Ocular Hx:	3 episodes of left eye redness and photophobia in the past year (self-resolved; never evaluated)
Prior therapy:	Anti-TNF (adalimumab) stopped 18 months after secondary loss of response; switched to vedolizumab

Discussion Prompts

1. Gut in remission, new back + eye symptoms — how does the assessment change?
2. Activity-independent EIMs: axial SpA + recurrent uveitis — both off anti-TNF
3. Was adalimumab masking these EIMs? Vedolizumab is gut-selective — does not treat systemic disease
4. Who leads management now: GI, rheumatology, or ophthalmology?
5. What is the shared-pathway treatment rationale for this case (class-level)?
6. What monitoring and follow-up are essential to prevent flares and complications?

Clinical Pearl: EIM flare during gut remission is not always GI treatment failure. Gut-selective therapy may unmask EIMs previously suppressed by anti-TNF, and management may require a specialty-directed add-on rather than IBD dose escalation or switching back.

CRP = C-reactive protein.

Faggiani I, et al. *Biomedicines.* 2024;12(8):1839. Gordon H, et al. *J Crohns Colitis.* 2024;18(1):1-37. Nardone OM, et al. *Aliment Pharmacol Ther.* 2025;61(12):1854-1871.

CME OUTFITTERS

Operationalizing EIM Screening: Who, When, and How

WHO screens?

- **Nurse/MA intake:** brief symptom prompt at check-in (joint pain, skin changes, eye symptoms)
- **APP (PA/NP):** focused 6-domain EIM review; document findings and trends
- **Physician:** review flagged items; expand workup as needed
- **APP as connective tissue** across the care team — especially in community practice

WHEN to screen?

- **Brief screen (nurse/APP):** every IBD visit — no exceptions
- **Annual full screen:** additional screening with major disease or treatment change
- **Targeted screen:** when switching or stopping biologics (anti-TNF masking risk)
- Anytime patient mentions new symptom outside the GI tract

HOW to document?

- Active EIMs on the problem list — separate from IBD diagnosis
- Referral log: date sent, specialty, urgency, response received
- Document whether symptoms appear activity-linked or activity-independent — this helps guide treatment discussion
- Shared summary note accessible to all treating specialists

Community practice reality:

What ***actually*** fits into a 15-min follow-up?

Nurse intake prompt + one open EIM question by APP = achievable without extending visit time.

MA = medical assistant; PA = physician associate/nurse practitioner; APP = advanced practice professional.

Bokaee SA, et al. *Cureus.* 2026;18(1):e102305. Gordon H, et al. *J Crohns Colitis.* 2024;18(1):1-37.

CME OUTFITTERS

Referral Triggers and Red Flags

OCULAR

Urgent / same day referral if uveitis suspected

Trigger: Painful red eye, photophobia, or vision change, or a red eye

Ophthalmology: Treat presumed uveitis as urgent; episcleritis is usually less urgent and often parallels IBD activity but slit-lamp confirmation is still needed to distinguish it from uveitis

MUSCULOSKELETAL

Early rheumatology referral within 2–4 weeks

Trigger: Inflammatory back pain (young onset, >30 min morning stiffness, improves with activity); or persistent inflammatory peripheral joint swelling

Rheumatology: Axial SpA can progress independently in IBD; early therapy reduces structural joint damage

DERMATOLOGIC

Prompt dermatology review; referral within 1 week

Trigger: Rapidly enlarging, ulcerating, severely painful, or necrotic skin lesion at any site; consider pyoderma gangrenosum, especially in a person with IBD

Dermatology: Avoid wide or aggressive surgical debridement during active PG because pathergy can worsen lesions; specialist wound care is appropriate

HEPATOBILIARY

Prompt hepatology evaluation; referral within 2–4 weeks

Trigger: Unexplained cholestatic liver tests, especially elevated ALP and/or GGT out of proportion to AST/ALT, particularly if persistent or recurrent in a patient with IBD

Hepatology + MRCP: PSC workup needed (hepatobiliary imaging plus MRCP); IBD + PSC has distinct colorectal cancer surveillance implications

ALP = alkaline phosphatase; ALT = alanine aminotransferase; AST = aspartate aminotransferase; GGT = gamma-glutamyl transferase; MRCP = magnetic resonance cholangiopancreatography.

Bokaee SA, et al. *Cureus.* 2026;18(1):e102305. Chhibba T, et al. *J Crohns Colitis.* 2025;19(1):jjaf009. Gordon H, et al. *J Crohns Colitis.* 2024;18(1):1-37. Nielsen VW, et al. *J Crohns Colitis.* 2025;19(5):jjaf066. Maverickx N, et al. *NEJM Evid.* 2024;3(3):EVIDoa2300337.

CME OUTFITTERS

Summary of Biologics in IBD-Associated EIMs

	Anti-TNF*				Anti-integrins*		JAK*	IL-12/23*
	IFX	ADA	CZP	Goli	VDZ	NTX	TOFA	UST
Arthritis	■	■	■	■	□	■	■	■
SpA	■	■	■	■	■	■	□	■
EN	□	□	□	□	■	■	□	□
PG	■	■	■	■	■	■	□	□
Uveitis	■	■	■	■	■	■	□	□

*None of the agents listed are FDA-approved for use in EN or PG. Infliximab, certolizumab, golimumab, tofacitinib, ustekinumab, vedolizumab, and natalizumab are not FDA-approved for uveitis. Vedolizumab and natalizumab are not FDA-approved for arthritis or SpA. Ustekinumab is not FDA-approved for axial SpA/AS. All use in these contexts is off-label.

■ Should be considered
□ May be considered
■ Cannot be recommended

ADA = adalimumab; CZP = certolizumab; Goli = golimumab; IFX = infliximab; IL = interleukin; JAK = Janus kinase; NTX = Natalizumab; TOFA = tofacitinib; UST =Ustekinumab; VDZ = vedolizumab.

Greuter T, et al. *Gut.* 2021;70(4):796-802.

CME OUTFITTERS

Future Directions: Emerging Therapeutics for EIMs in IBD

JAK Inhibitors

Approved for IBD — EIM data emerging

- Upadacitinib, tofacitinib, and filgotinib approved for IBD; growing evidence for musculoskeletal and skin EIMs
- Upadacitinib phase 3 data (UC): EIM improvement as secondary endpoint — axial and peripheral arthritis signal
- Broad JAK-STAT pathway suppression may address multiple EIM subtypes simultaneously
- Limitation: infection and thrombosis risk; EIM-specific trial data still limited

Selective IL-23 Inhibitors

Approved for IBD — nuanced EIM picture

- Risankizumab and mirikizumab: class data suggests benefit for skin EIMs (EN, PG) and uveitis
- IL-23p19 inhibitors show no meaningful benefit for axial SpA — axial disease requires IL-17 or TNF pathway
- Guselkumab: additional CD64 binding on myeloid cells — unique mechanism; approved for psoriatic arthritis
- IL-23 inhibitors may help skin/ocular EIMs but will not treat axial disease

⚠ **Does not treat axial SpA**

Dual Biologic Therapy

Early phase — investigational

- Combinations of IL-23 inhibitors + JAK inhibitors or TNF inhibitors entering early-phase trials for refractory IBD
- Rationale: complementary pathway inhibition — IL-23 blockade + broad JAK-STAT suppression
- Potential relevance for patients with both gut disease and systemic EIM burden
- No EIM-specific outcomes data yet; safety profile under investigation

Precision & Emerging Targeted Approaches

Horizon — early research

- Tulisokibart (anti-TL1A): novel investigational mechanism in Phase 3 trials for UC and CD; early signals suggest potential benefit across IBD and immune-mediated inflammatory diseases including axial SpA
- Genetic risk stratification: identifying IBD patients at highest EIM risk before manifestations occur
- Shared pathway targeting: leveraging IL-23/IL-17/TNF overlap between IBD and rheumatologic/dermatologic disease
- Goal: move from reactive to proactive EIM management using molecular and clinical phenotyping

TL1A = Tumor necrosis factor-like cytokine 1A.

Fousekis FS, et al. *Therap Adv Gastroenterol.* 2025;18:17562848251393391. Gordon H, et al. *J Crohns Colitis.* 2024;18(1):1-37. Khrom M, et al. *Gastroenterology.* 2024;167(2):315-332. Nardone OM, et al. *Aliment Pharmacol Ther.* 2025;61(12):1854-1871.

CME OUTFITTERS

Key Takeaways



1. **Common**

   EIMs are frequent and may precede GI symptoms

2. **Independent course**

   Some EIMs track with bowel activity; others do not

3. **Screen every visit**

   Routine review at each visit should be the minimum standard

4. **Pause before switching**

   Consider unmasking or paradoxical effects before changing therapy

Recognize early, screen consistently, and treat thoughtfully!

CME OUTFITTERS

SMART Goals

Specific, Measurable, Attainable, Relevant, Timely

Put information into action! Consider the following goals; then set a time frame that fits with your work environment and a reasonable improvement target that aligns with your patient population.

- **Increase** the percentage of people with IBD who are screened for EIMs at every clinic visit using a standardized intake prompt
- **Improve** documentation of active EIMs as separate diagnoses on the problem list for people with IBD
- **Ensure** that people with IBD who develop new systemic symptoms after a biologic switch receive specialty consultation prior to any therapy change

CME OUTFITTERS

Goals for Increased Interprofessional Communication and Collaboration



Establish clear communication channels



Commitment to evidence-based practices



Respect for other HCPs' unique knowledge and contribution



CME OUTFITTERS

Evans S, et al. *J Interprof Care*. February 6, 2025 [Epub ahead of print]. Bowman KS, et al. *Behav Anal Pract*. 2021;14(4):1191–1208. Price JR, et al. *Sch Psychol*. 2024;39(4):419–432.

Goals for Increased Interprofessional Communication and Collaboration



Assess collaboration competency and willingness to accept feedback from other HCPs



Patient and caregiver values, preferences, and needs are considered by all HCPs

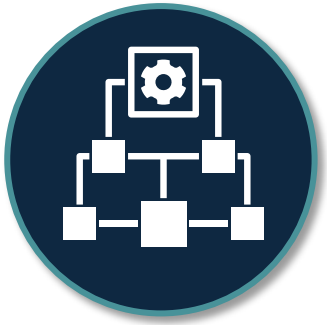

Use frameworks for structured communication

CME OUTFITTERS

Evans S, et al. *J Interprof Care*. February 6, 2025 [Epub ahead of print]. Bowman KS, et al. *Behav Anal Pract*. 2021;14(4):1191–1208. Price JR, et al. *Sch Psychol*. 2024;39(4):419–432.

CME OUTFITTERS

Additional Resources

Visit www.cmeoutfitters.com for clinical information and certified educational activities



CME OUTFITTERS

Visit the
Gastroenterology Hub

Free resources and education
for health care professionals and patients

https://www.cmeoutfitters.com/practice/gastroenterology-hub/



To Receive Credit

To receive CME/CE credit for this activity, participants must complete the post-test and evaluation online.

Participants will be able to download and print their certificate immediately upon completion.



CME CAST

Other episodes in this series include:

EPISODE 1

Beyond Symptoms — The Hidden Burden of IBD and the Future of Disease Modification

EPISODE 2

Fibrosis in IBD — Pathogenesis, Risk Stratification, and Objective Monitoring